



PATIENT

Freddy NHS

PRESENTING CLINICAL SIGNS

History: Continuous murmur heard on auscultation; palpable regurgitation felt through chest wall. Doing well.

SPECIES

Canine

RADIOGRAPHIC FINDINGS *NOTE: Images submitted for supplemental cardiac information only. Right-sided cardiomegaly with a bulge in the region of the MPA.

BREED

Terrier Mix

ELECTROCARDIOGRAPHIC FINDINGS

A six lead ECG is available at 50mm/s; 10mm/mV. The average heart rate is 80bpm (range 55-103bpm). The rhythm is sinus in origin, with a p for every QRS complex and vice versa. The P wave morphology is positive with a normal dimension. Normal PR. The QRS morphology is isoelectric. MEA is shifted right. No ectopic beats, pauses or dysrhythmias observed. ECG diagnosis: Normal sinus rhythm with respiratory variation. Right axis deviation.

SEX

Male Neutered

ECHOCARDIOGRAM FINDINGS

2D, m-mode, color flow and doppler imaging is available. Normal mitral valve leaflets with no obvious prolapse into the left atrial lumen. No obvious mitral regurgitation. Normal left atrial dimension. Normal LV diameter with normal myocardial function. The LV wall appears normal. The tricuspid valve appears mildly elongated with no insufficiency seen. Moderate right atrial dilation. Significant right ventricular hypertrophy and remodeling indicative of pressure overload. Septal flattening noted. Right ventricular dilation. Pulmonic outflow velocities are elevated at the level of the valve. The pulmonic valve appears severely thickened, tethered and stenotic. There is significant post-stenotic dilation of the main pulmonary artery and branches. Trivial pulmonic insufficiency. The aortic valve appears to have normal morphology and mobility. No obvious cardiac shunts are present. No pericardial or pleural effusion noted.

AGE

4 years

WEIGHT

21.6lbs

INTERPRETED BY

Maggie Machen Lamy, DVM, DACVIM (Cardiology)

CARDIAC CHART

IMAGING PERFORMED BY

Loetitia St-Jacques, LVT/RVT

CANINE CARDIAC PARAMETERS	MR VMAX (m/s)	TR VMAX (m/s)	LA/AO (Boon method)	LA/AO (Heart Base; Swe)	FS (%)	EF (%)	EPSS (cm)
NORMAL PARAMETER	4.5-5.5	<2.7	1.3	<1.6	28-40	40-100	<0.6
PATIENT	NA	NA	NM	1.3	52	90	NM
CANINE CARDIAC PARAMETERS	HR (BPM)	AV VMAX (m/s)	PV MAX (m/s)	BODY WEIGHT (kg)	LA 2D short axis Base view (cm)	LVIDd Avg; 2D and m-mode short axis (cm)	LVIDs Avg; 2D and m-mode short axis (cm)
NORMAL PARAMETER	50-100	0.7-1.7	0.7-1.6	BELOW	BELOW	BELOW	BELOW
PATIENT	NM	1.3	5.8	9.8	2.2	2.2	1.0
*Normal chamber parameters expressed as a mean value (SD)				3	1.27 (5.3)	2.46 (2.46)	1.36 (5.5)
BODY WEIGHT DEPENDENT PARAMETERS				5	1.40 (4.5)	2.74 (5.2)	1.60 (4.7)
*Note: All measurements based upon multi-modal images and methods. An average value is reported.				10	1.50 (3.8)	3.27 (3.5)	2.06 (3.1)
				15	1.83 (2.0)	3.71 (2.4)	2.43 (2.1)
				20	2.02 (1.9)	4.14 (2.2)	2.80 (2.0)
				25	2.18 (2.4)	4.48 (2.9)	3.10 (2.5)
				30	2.33 (3.3)	4.83 (3.9)	3.39 (3.4)
				35	2.48 (4.3)	5.17 (5.0)	3.69 (4.5)
				40	2.62 (5.2)	5.48 (6.1)	3.96 (5.4)

Adapted from June Boon, Veterinary Echocardiography, 1998
 Rishniw M and Hollis NE, J Vet Intern Med 2000; 14:429-435
 Hansson et al, Vet Rad and Ultrasound 2002
 Bonagura et al. Echocardiography: principles of interpretation, Vet Clin North Am 15:1177, 1995

INVOICE

28849

DATE

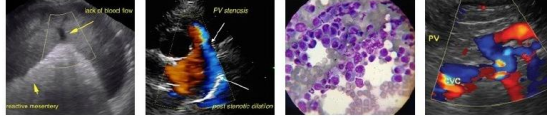
2/7/23

HOSPITAL NAME

Nevada Humane Society

REFERRING VET

Dr. Matzke



PATIENT

	50	2.88 (7.1)	6.07 (8.3)	4.46 (7.4)
--	----	------------	------------	------------

Freddy NHS

SPECIES

Canine

BREED

Terrier Mix

SEX

Male Neutered

AGE

4 years

WEIGHT

21.6lbs

INTERPRETED BY

Maggie Machen Lamy,
DVM, DACVIM
(Cardiology)

IMAGING PERFORMED BY

Loetitia St-Jacques,
LVT/RVT

HOSPITAL NAME

Nevada Humane
Society

REFERRING VET

Dr. Matzke

INVOICE

28849

DATE

2/7/23

INTERPRETATION OF THE FINDINGS & FURTHER RECOMMENDATIONS

The cause of the murmur is severe valvular pulmonic stenosis. The degree of obstruction is severe based upon the velocity/pressure gradient across the pulmonic valve and the secondary hypertrophy and remodeling of the right ventricle. There is significant RA dilation, suggesting the risk for CHF in the future is elevated and may likely limit lifespan. No other congenital abnormalities were visualized. The ECG is unremarkable with a normal sinus rhythm. A right axis deviation is common in cases of RV hypertrophy and is a benign finding.

Referral for balloon valvuloplasty should be considered in this patient as the gold standard therapeutic option for this condition and may improve long term outcome and delay onset of clinical signs (including exertional syncope and right-sided congestive heart failure). If surgery is not elected, this patient's condition will likely limit lifespan, with many severe PS cases developing CHF by mid-life. Regardless, medical management with atenolol is recommended to decrease heart rate and lessen the obstruction as below. It is worth noting that the resting heart rate is relatively slow and potentially within the target range. If this is a consistent finding, the drug may not need to be utilized unless symptoms develop. Serial monitoring is advised.

Monitor for development of associated clinical signs (collapse, abdominal distention, cough, labored breathing). Mild exercise restriction is advised.

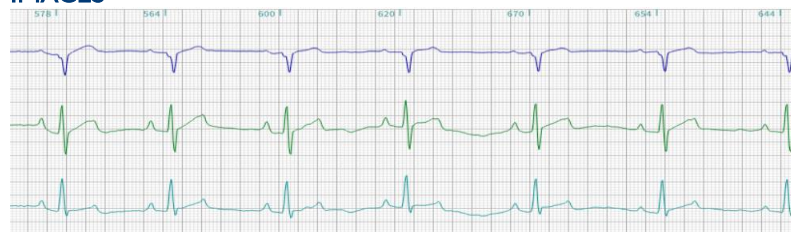Anesthetic risk is mild to moderate at this time. Avoid heart rate stimulating drugs such as atropine or glycopyrrolate unless absolutely necessary. Avoid vasodilators such as acepromazine. Mild IV fluid restriction is advised. Cardiac protective drug choices (opioid/benzodiazepine premedication, propofol or alfaxalone induction, isoflurane gas) are recommended. Pre-oxygenate for 5-10 minutes prior to induction and recover in O2 if possible. Monitor for arrhythmias, hypotension, and hypoxia both intra and post-operatively and intervene as necessary.

PLAN

If resting HR is >130bpm, institute atenolol to effect: 25mg tabs, ¼ tab PO BID to start (up-titrate to desired effect). Goal is to suppress heart rate <120-140bpm even with stress/activity. Baseline chest radiographs and ECG are recommended. Referral for balloon valvuloplasty ASAP if desired.

If surgery is declined, recommend recheck echocardiogram in 6 months to assess for progression, response to medication.

IMAGES





Portable Animal Western Sonography, Inc.

IMAGING PERFORMED BY

pawsonography@gmail.com 530-786-8340

PATIENT

Freddy NHS

SPECIES

Canine

BREED

Terrier Mix

SEX

Male Neutered

AGE

4 years

WEIGHT

21.6lbs

INTERPRETED BY

Maggie Machen Lamy,
DVM, DACVIM
(Cardiology)

IMAGING PERFORMED BY

Loetitia St-Jacques,
LVT/RVT

HOSPITAL NAME

Nevada Humane
Society

REFERRING VET

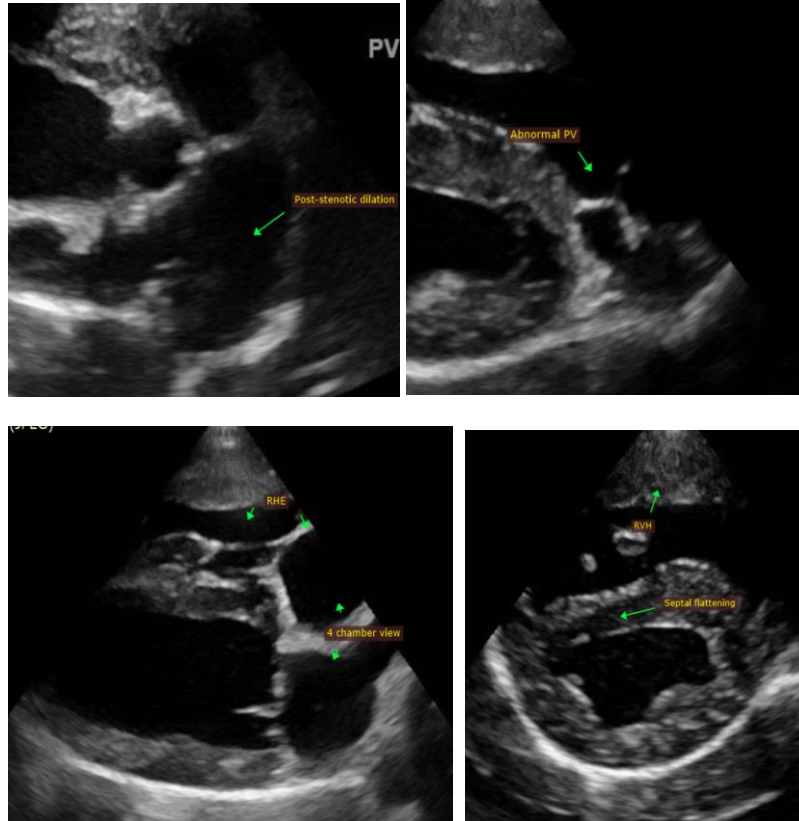
Dr. Matzke

INVOICE

28849

DATE

2/7/23



The information and recommendations provided are based on the images presented by the referring veterinarian. No evaluation can be communicated regarding pathology that was not visible in the image/video clips provided.

Thank you for this referral. This report was generated using transcription software, and minor dictation errors may be present. If the clinical or image interpretation does not parallel your findings or if I can be of any further assistance, please contact me.

Maggie Machen Lamy, DVM
Diplomate of the American College of Veterinary Internal Medicine (Cardiology)
info@sonopath.com